

## Poster 28

### Acral Merkel Cell Carcinoma: Recurrence and Survival after Multidisciplinary Treatment

Samuel E. Broida, MD, Xiao T. Chen, MD, Brian D. Wahlig, MD, Steven Moran, MD, Matthew T. Houdek, MD

**Introduction:** Merkel cell carcinoma (MCC) is a rare, aggressive non-melanoma skin cancer arising from cutaneous neuroendocrine cells with a propensity for local and distant disease recurrence. Currently there is a paucity of data examining the outcome of MCC arising from acral regions of the body including the hand, wrist, foot, and ankle. The purpose of the present study was to examine the treatment outcomes of patients with acral MCC.

**Patients and Methods:** A single-institution, retrospective review was conducted on 270 MCC patients, of which 30 (11.1%) had acral MCC. The group included 20 males and 10 females, with a mean age of  $72 \pm 12$  years at the time of biopsy. All histology was confirmed by fellowship trained dermatopathologists. Tumors were located on the hand (n=13), finger/thumb (n=8), wrist (n=3), ankle (n=6), and foot (n=1).

**Results:** Twenty-six patients were treated with wide local excision, including one 5<sup>th</sup> finger ray amputation and 25 non-amputation resections. Three patients received Mohs micrographic surgery for lesions of the hand or finger. Sentinel lymph node (SLN) biopsy was performed in 27 patients with positive nodal disease in 10 cases (37%), only one of whom was treated with lymph node dissection. Three of 18 patients (16.6%) without palpable lymphadenopathy had positive SLN. Pre-operative PET imaging was negative for nodal disease in 15/17 (88.2%) patients, yet SLN biopsy was positive in two (13.3%) of the patients with negative PET scans. Adjuvant radiotherapy was delivered to the primary site in 21/30 (70%) patients and additionally to the regional lymph node basin in 11/21 (52.4%). Adjuvant systemic chemotherapy was delivered to 4 of 30 patients. Overall, there were no local recurrences, 9 (30%) regional recurrences (mean 16.4 months), and 9 (30%) distant recurrences (mean 14.2 months). Recurrence-free survival was 62.5% at 1 year, 54.8% at 3 years, and 49.3% at 5 years (Figure 1). Disease-specific survival was 93.2% at 1 year, 79.8% at 3 years, and 79.8% at 5 years (Figure 2).

**Conclusion:** Merkel cell carcinoma (MCC) is a rare cutaneous neuroendocrine carcinoma with a high propensity for regional nodal spread and a predilection towards sun-exposed areas, including the hand and wrist. Clinical examination and PET imaging are unreliable for detecting regional lymph node involvement. Sentinel lymph node biopsy should be performed in all patients – even those with negative PET scans - due to the potential for micrometastatic disease. Despite aggressive treatment including margin-negative resection, adjuvant radiotherapy to the primary site and regional nodes, and chemotherapy, acral MCC carries a significant rate of recurrence and disease-specific mortality within five years of diagnosis. However, likelihood of local recurrence is low even with non-amputative resections.

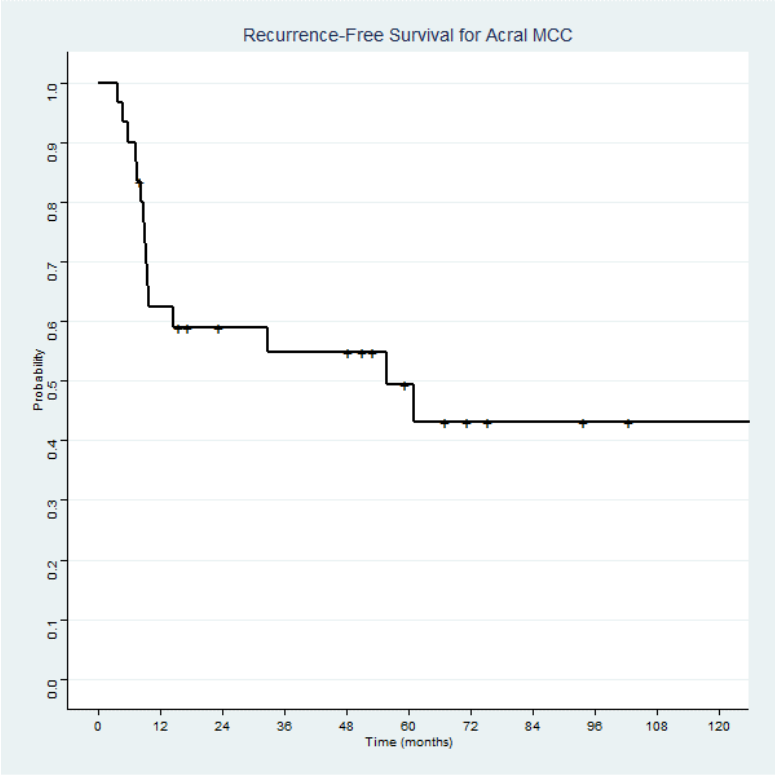


Figure 1 - Recurrence-free survival following multidisciplinary treatment of acral Merkel cell carcinoma

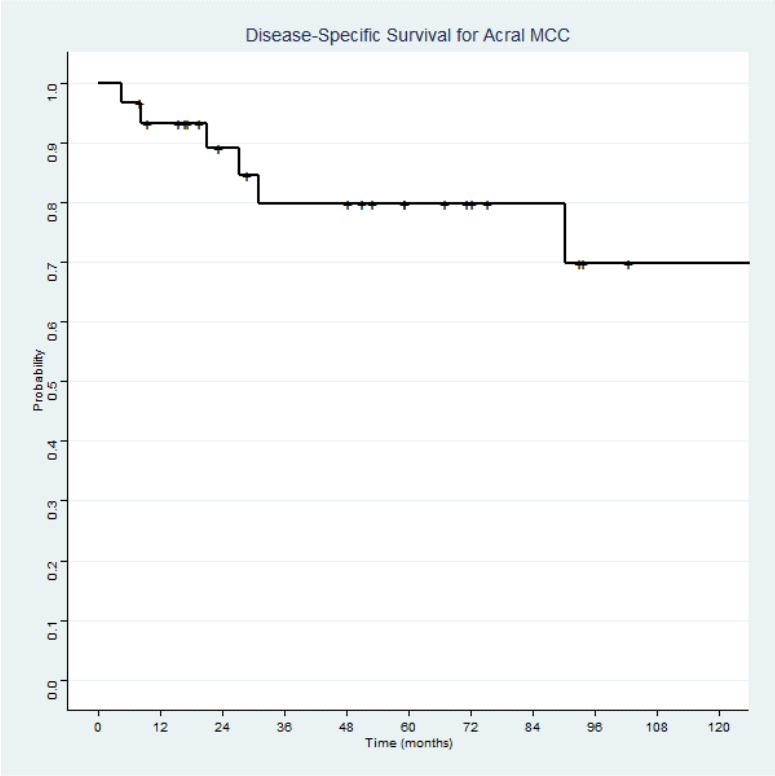


Figure 2 - Disease-specific survival following multidisciplinary treatment of acral Merkel cell carcinoma